

Lung Cancer Staging

Jean Bustamante Alvarez, MD, MS
Clinical Instructor of Health Sciences
Department of Internal Medicine
Division of Hematology and Medical Oncology
The Ohio State University Wexner Medical Center

Epidemiology

- **Leading cause of cancer death in the United States.**
- **An estimated of 228,820 new cases will be diagnosed in 2020 and 135,720 deaths.**
- **Only 19% of cases with lung cancer are alive 5 years or more after diagnosis including small and non-small cell lung cancer.**
- **If eligible for targeted therapy 5 year survival rates range from 15% to 50% depending on the biomarker.**

Adv Exp Med Biol. 2016;893:1-19. Cancer statistics, 2020. CA Cancer J Clin 2020;70: 7-30.

Risk Factors

- Smoking tobacco. (85%-90% of cases are caused by smoking).
- Exposed non-smokers have an increased relative risk (RR=1.24).
- Exposition to asbestos and radon gas.
- Exposition to other carcinogenics: arsenic, chromium, nickel, coal smoke, soot, cadmium, beryllium, silica and diesel fumes.

Lancet Oncol. 2009 May;10(5):453-4.

Lung Cancer Screening:

- Risk assessment.
- Recommended for high risk groups LDCT:

Group 1:

- Age 55-77 years and
- ≥ 30 pack-year history of smoking.
- Smoking cessation < 15 years.

Group 2:

- ≥ 50 years and
- ≥ 20 pack-year history of smoking and
- Additional risk factors.

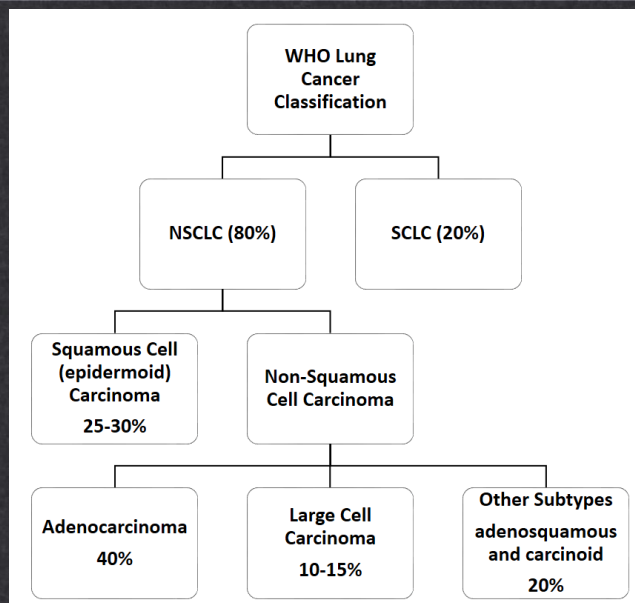
Decreased mortality rate by 20%

NCCN Clinical Practice Guidelines in Oncology. Version 1. 2020-May14,2019.

Clinical presentation:

- Cough
- Hemoptysis
- Dyspnea
- Weight loss
- Chest pain

Lung Cancer Classification:



J Thorac Oncol. 2015 Sep;10(9):1243-1260. Cancer Epidemiol Biomarkers Prev 2019;28:1563-79

Importance of Staging:

- Prognosis.
- Intent of the treatment (Curative vs Palliative).
- Treatment strategy: multimodality vs chemo-radiation vs systemic therapy alone.

Case study:

- 80 y.o female with PMH of COPD and 35 pack years history of smoking who presented with cough in 2018 treated several times as a COPD exacerbation with antibiotics and steroids.
- In January 2019 a CXR showed a lung nodule → referred to interventional pulmonology.
- CT Chest revealed mediastinal adenopathy (subcarinal lymph node measured 2.1 x 3.1 cm.) and LUL 2.1 cm mass.

Initial evaluation:

- H&P (assess performance status and weight loss).
- CT chest and upper abdomen with contrast.
- Biopsy and Pathological Review.
- CBC, CMP
- PFT and stress test in certain situations when surgery is considered.

NCCN Clinical Practice Guidelines in Oncology. Version 1. 2020-May14,2019.

Initial evaluation:

- FDG-PET/CT scan and CT Chest and abdomen including adrenal glands.
- Positive distant disease → need pathological confirmation.
- Positive mediastinum → needs pathological confirmation.
- Pathological mediastinal evaluation with bronchoscopy (EBUS/EUS), (intraoperative if possible), mediastinoscopy, CT guided biopsy depending on the case.
- Brain imaging (MRI with contrast or CT head with contrast).

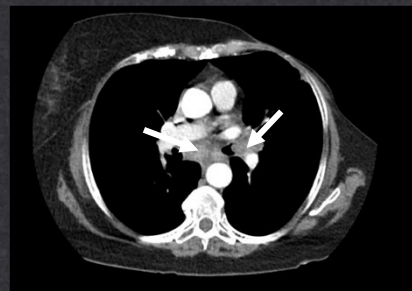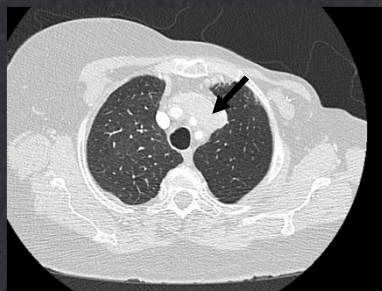
NCCN Clinical Practice Guidelines in Oncology. Version 1. 2020-May14,2019.

Pretreatment assessment:

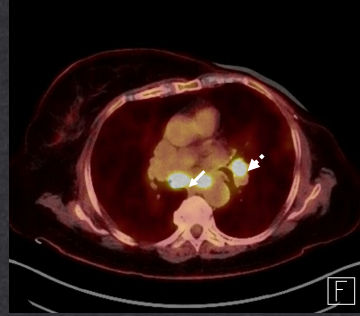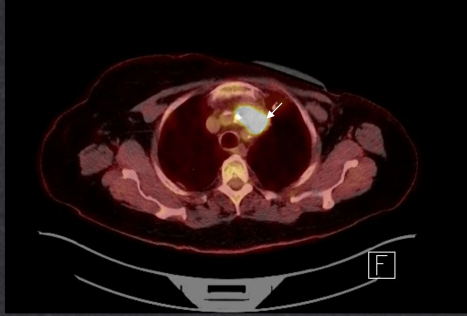
Mediastinal Assessment:

- Mediastinal evaluation (N2) prior to surgery is required.
- CT/PET :
 - Solid nodule <1 cm or purely nonsolid nodule < 3cm and LNs not PET avid – biopsy optional. → surgery + LN sampling/dissection.
 - Otherwise mediastinal LN sampling recommended.
- Mediastinal LN positive → neoadjuvant/induction or definitive non-surgical treatment.
- Preoperatively, mediastinoscopy remains the gold standard.
- Bronchoscopy with EBUS ± EUS commonly used.

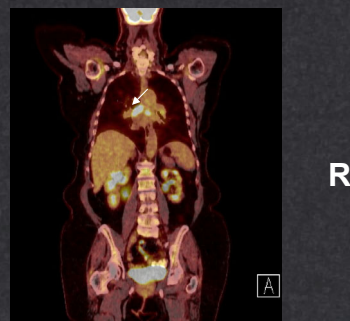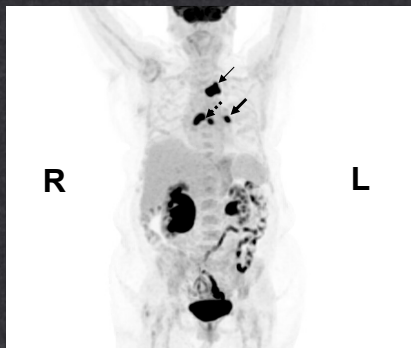
Case study: CT chest with contrast:



PET/CT scan results:



PET/CT scan results:



Results of PET staging

- In 20 (of 102 pts), 29 hot spots outside the mediastinum were detected
- In 11 patients distant metastasis were found not otherwise seen by standard methods.
- 9 false positive (4 colon, 2 lung, 1 adrenal, liver, rib).
- 20 patients down staged.
- 64 patients upstaged.

Method	Sensitivity	Specificity	Accuracy
CT	75% (60-90)	66% (55-77)	69% (60-78)
PET	91% (81-100)	86% (78-94)	87% (80-94)
CT and PET	94% (86-100)	86% (78-94)	88% (82-94)

NEJM 2000;343:254-61. Eur Radiol (2007) 17: 23-32.

PET conclusions

- PET (and preferably integrated PET/CT) improves mediastinal staging.
- PET and PET/CT may also pick up additional unsuspected metastatic lesions.
- This technique does NOT supplant mediastinoscopy or biopsy.
- Early data suggests that PET may predict clinical response.



Which diagnostic technique to use?

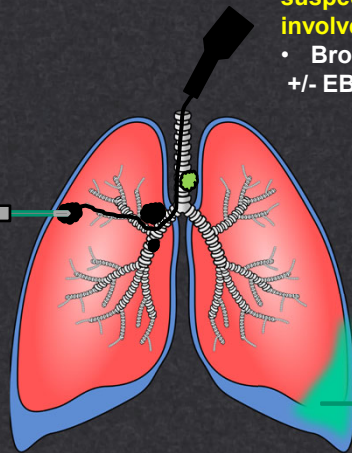
- Depends on:
 - Size and location of the tumor.
 - Presence of mediastinal or distant disease.
 - Patient characteristics such as baseline pulmonary pathologies or other significant comorbidities.
 - Local experience and expertise.
 - Invasiveness and risks of the procedures.

Diagnostic modalities:

Peripheral nodules:

- Transthoracic needle aspiration.
- Navigational bronchoscopy and radial EBUS.
- VATS and open surgical biopsy.

-  Tumor
-  Lymph Nodes



Central masses And suspected endobronchial involvement:

- Bronchoscopy +/- EBUS/EUS.

Suspected nodal disease:

- EBUS, EUS.
- Navigational bronchoscopy, or mediastinoscopy.

Associated pleural effusion:

- Thoracentesis with cytology.
- If negative, repeat thoracentesis and/or VATS before starting curative intent therapy.

Case study

- Patient underwent rigid bronchoscopy with biopsy and mechanical debulking of the left mainstream tumor.
- Endobronchial ultrasound was used to examine mediastinal lymph nodes and station 7 (subcarinal) was biopsied.
- Left lung mass biopsy: adenosquamous carcinoma.
- Station 7 lymph node: positive for adenocarcinoma of possible lung primary with rare squamous differentiation.

Pathological review:

- Histology and immunohistochemistry stains:
 - Adenocarcinoma: TTF-1, Napsin A.
 - Squamous cell carcinoma: p40, p63.
 - Small cell lung cancer: TTF-1, chromogranin and synaptophysin and high K67 proliferative marker.
 - Typical and atypical carcinoid tumors: chromogranin and synaptophysin and intermediate to low Ki67.

Pathological review:

- PD-L1 testing: Tumor proportion score of 99%.
- Molecular testing for actionable mutations:
 1. *EGFR, ALK, ROS, BRAF, NTRK* gene alterations.
 2. Other: *RET, MET, ERBB2*.

TNM Staging System:

T→ denotes the size and extent of the primary tumor.

N→ denotes the spread pattern to the nearby lymph nodes.

M→ denotes the spread to distant sites.

Primary Tumor or T:

TX: primary tumor cannot be assessed.

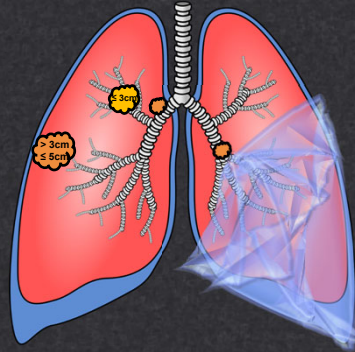
T0: No evidence of primary tumor

Tis: Carcinoma *in situ*

T1 ≤ 3 cm and no invasion into the main bronchus.

T2 > 3 cm but ≤ 5 cm or

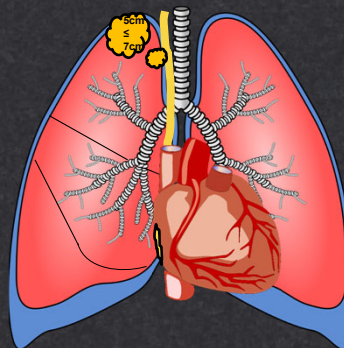
- Involves main bronchus
- Visceral pleural invasion
- Associated atelectasis or obstructive pneumonitis extending to hilar region.



Primary Tumor or T:

T3 > 5 cm but ≤ 7 cm or invading:

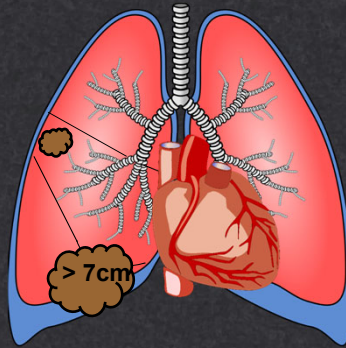
- Parietal pleura.
- Chest wall (including superior sulcus tumors).
- Phrenic nerve.
- Parietal pericardium.
- Separate tumor nodule(s) in the same lobe as the primary.



Primary Tumor or T:

T4 > 7cm or any size invading one or more of the following:

- Diaphragm.
- Mediastinum, heart and/or great vessels.
- Trachea and carina.
- Esophagus.
- Recurrent laryngeal nerve.
- Vertebral body.
- Separate tumor nodules in an ipsilateral lobe different from that of the primary.

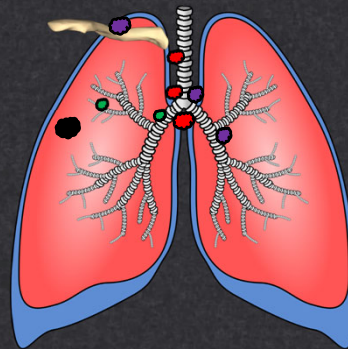


Lymph Nodes or N:

NX: regional lymph nodes a cannot be assessed.

N0: No regional lymph node metastasis.

- **N1:** Ipsilateral peribronchial, ipsilateral hilar lymph node(s) and intrapulmonary.
- **N2:** Ipsilateral mediastinal or subcarinal lymph node(s)
- **N3:** Contralateral mediastinal, hilar, or ipsilateral or contralateral scalene or supraclavicular lymph nodes.



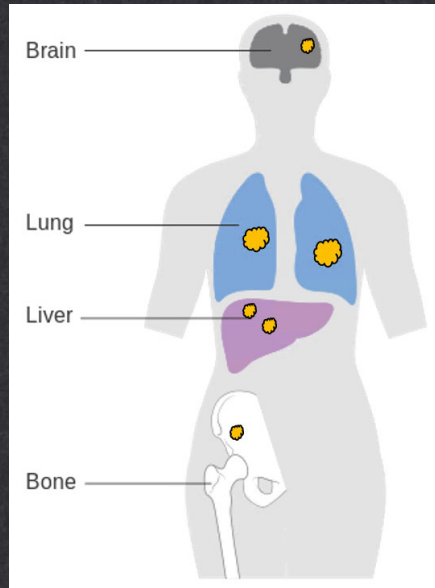
● Primary tumor

Distant metastasis or M

- M1a = Separate tumor nodule(s) in a contralateral lobe; tumor with pleural or pericardial nodules or malignant pleural or pericardial effusion.

- M1b = Single extrathoracic metastases in a single organ.

- M1c = Multiple extrathoracic metastases in a single or multiple organs.



Case study:

- cT2, N2, M0.
- Subcarinal lymph node measures → right side 2.1 x 3.1 cm and left side 1.6x1.6 cm.
- Considered non-surgical candidate due to N2 bulky lymphadenopathy and multi-station involved.
- Referred to Radiation Oncology for definitive concurrent chemoradiation with carboplatin and paclitaxel -->durvalumab.

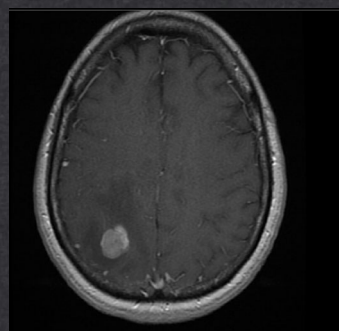
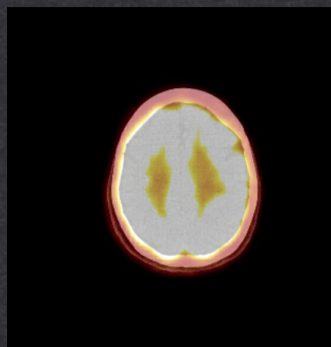
MRI brain with contrast:

- NCCN guidelines recommend evaluation of brain with MRI (~25% of patients either have or will develop brain metastasis):
 - Symptomatic suspicion
 - Stage Ib: optional
 - Stage ≥ 2 : mandatory

CT/PET

vs

Brain MRI



Staging and Prognosis

AJCC 8th Edition

Curative Intent

Palliative

Stage	T	N	M	24 months OS	60 months OS
IA1	T1mi or T1a	N0	M0	97%	92%
IA2	T1b, N0, M0	N0	M0	94%	83%
IA3	T1c	N0	M0	90%	77%
IB	T2a	N0	M0	87%	68%
IIA	T2b	N0	M0	79%	60%
IIB	T1 a,b,c	N1	M0	72%	53%
	T2a,b	N1	M0		
	T3	N0	M0		
IIIA	T1a,b,c	N2	M0	55%	36%
	T2a,b	N2	M0		
	T3	N1	M0		
	T4	N0	M0		
	T4	N1	M0		
IIIB	T1a,b,c	N3	M0	44%	26%
	T2a,b	N3	M0		
	T3	N2	M0		
	T4	N2	M0		
IIIC	T 3,4	N3	M0	24%	13%
IVA	Any T	Any N	M1a	23%	10%
	Any T	Any N	M1b		
IVB	Any T	Any N	M1c	10%	0%

Journal of Thoracic Oncology Vol. 11 No. 1: 39-51, J Thorac Cardiovasc Surg 2018;155:356-9

Treatment

Stage	T	N	M	Treatment
IA1	T1mi or T1a	N0	M0	Surgical resection or SABR (Stereotactic Ablative Radiotherapy)
IA2	T1b, N0, M0	N0	M0	
IA3	T1c	N0	M0	
IB	T2a	N0	M0	
IIA	T2b	N0	M0	Surgery + Chemotherapy (SABR± Adjuvant Chemotherapy)**
IIB	T1 a,b,c	N1	M0	
	T2a,b	N1	M0	
IIIA	T1 a,b,c	N2	M0	Neoadjuvant Chemotherapy → Surgery (selected N2*) or CRT → Durva if multilevel or bulky LN.
	T2 a, b	N2	M0	
	T3	N1	M0	
	T4	N0	M0	
	T4	N1	M0	
IIIB	T1a,b,c	N3	M0	Concurrent Chemoradiation → consolidation Durvalumab
	T2a,b	N3	M0	
	T3	N2	M0	
	T4	N2	M0	
IIIC	T 3, 4	N3	M0	Systemic therapy
IVA	Any T	Any N	M1a	
	Any T	Any N	M1b	
IVB	Any T	Any N	M1c	

*Single station and <3cm.
** If upstage to N2 during surgery consider PORT (Post Operative Radiation) following chemotherapy is indicated in positive margins as well.

Lung Cancer (2005)47, 81—83.
NCCN Clinical Practice Guidelines in Oncology. Version 1. 2020-May14,2019.

Conclusions:

- A multidisciplinary approach is important to better decide diagnostic and staging strategies.
- Typical staging testing includes:
 - CT chest abdomen and pelvis with contrast.
 - PET/CT which aides with bone disease identification +/- MRI
 - Brain MRI with contrast (CT head with contrast)
 - Mediastinal evaluation if no distant disease.
 - Pathological review including: IHC for histology subtypes, PD-L1 and molecular alteration (NGS, PCR, FISH, IHC).